

Use of indirect, 3-dimensional, Cold Atmospheric Plasma-Aerosol (CAP-A) in severe Acne. A Case Report.

Introduction:

Cold Atmospheric Plasma (CAP) is an ionized energetic state of matter in gaseous form with antimicrobial, anti-inflammatory and symptom relief properties. It is used for skin treatment of wounds, infection and inflammation, acne, rosacea, psoriasis, as well as different kind of eczema.

Indirect, 3-dimensional, Cold Atmospheric Plasma-Aerosol (CAP-A) represents the next step in the evolution of plasma technology: A patented technology creating an indirect 3-dimensional aerosol with cold plasma reaction products. Thus, CAP-A is an advanced contact free way to deliver cold plasma in a mist without heat transfer to the skin as a safe, non-invasive, and painless treatment within sessions of 3 minutes.

Moreover, CAP-A has a site-effect free powerful antimicrobial and healing effect without the use of chemicals or medications. Thus, CAP-A can be applied to a skin area of approximately 10 cm x 10 cm using a patented equipment classified by the EU Quality Management System Certificate as a Class IIa medical device*.

The device allows for a new treatment option for wounds, infection, inflammation and infection prophylaxis and supports the inactivation of microorganisms and enhances skin healing.

Preben Joffe (1), Robert Fuchs (2)

(1) Plasmoclean Test Center, Denmark, (2) Department of Research and Development, WK-MedTec GmbH, Germany

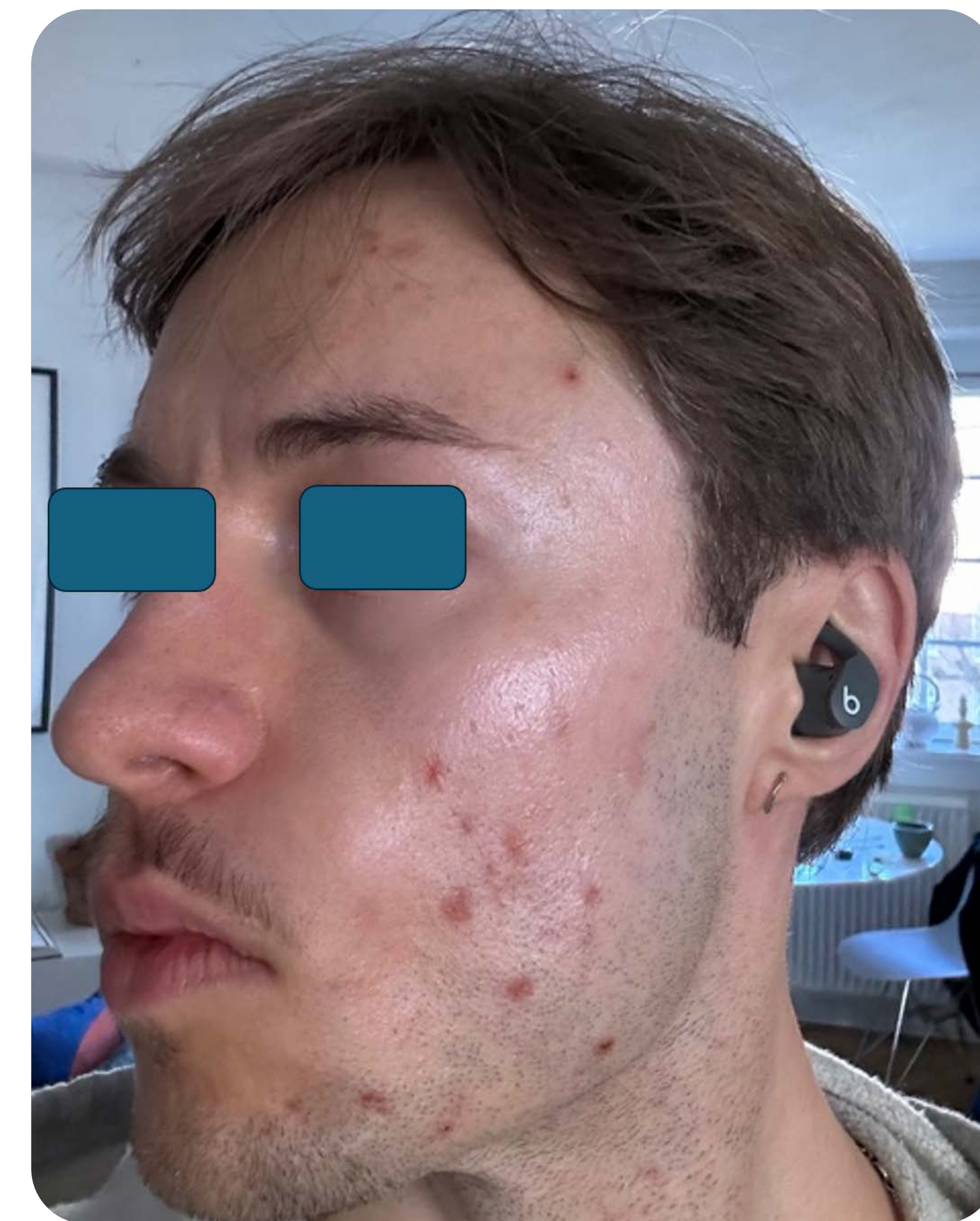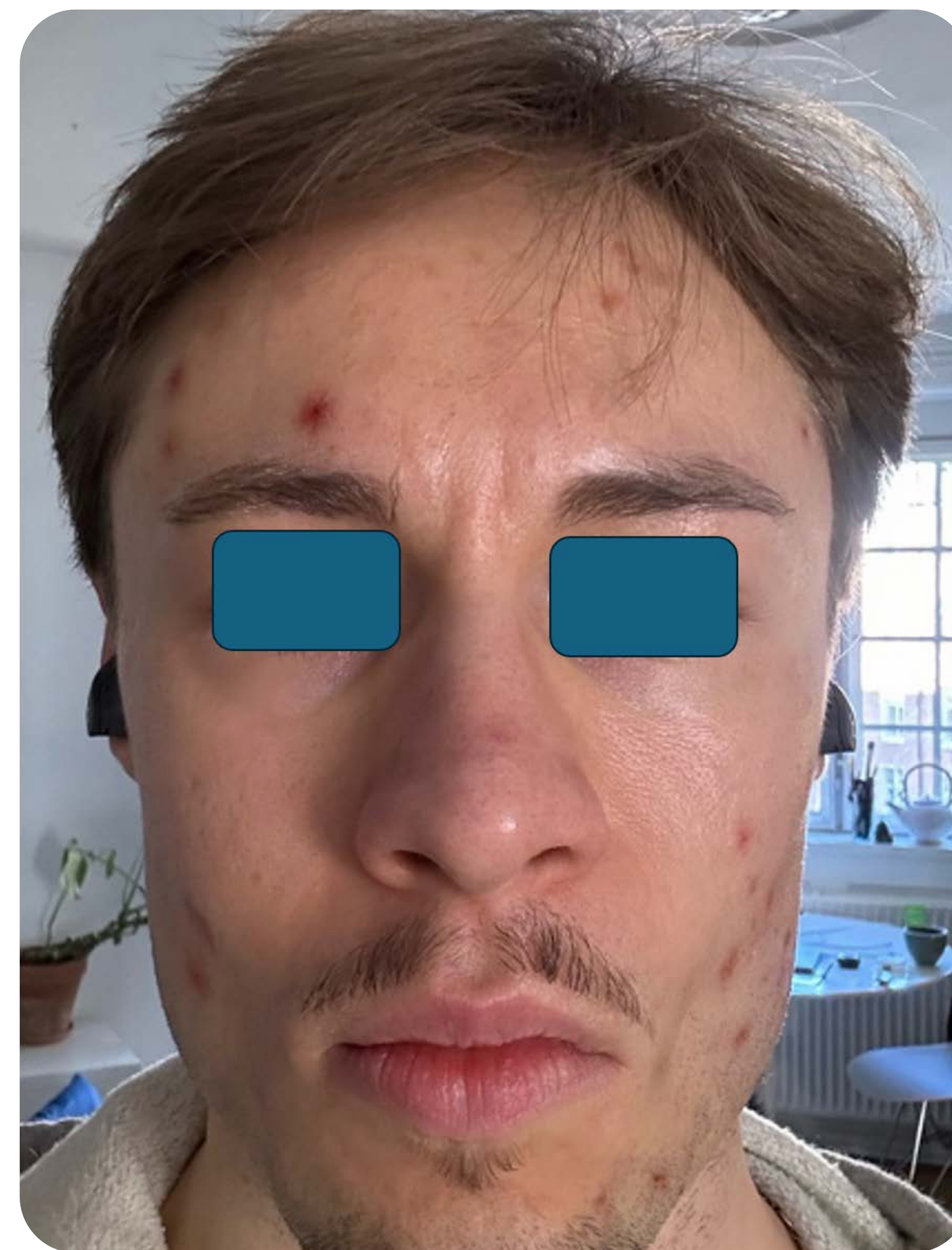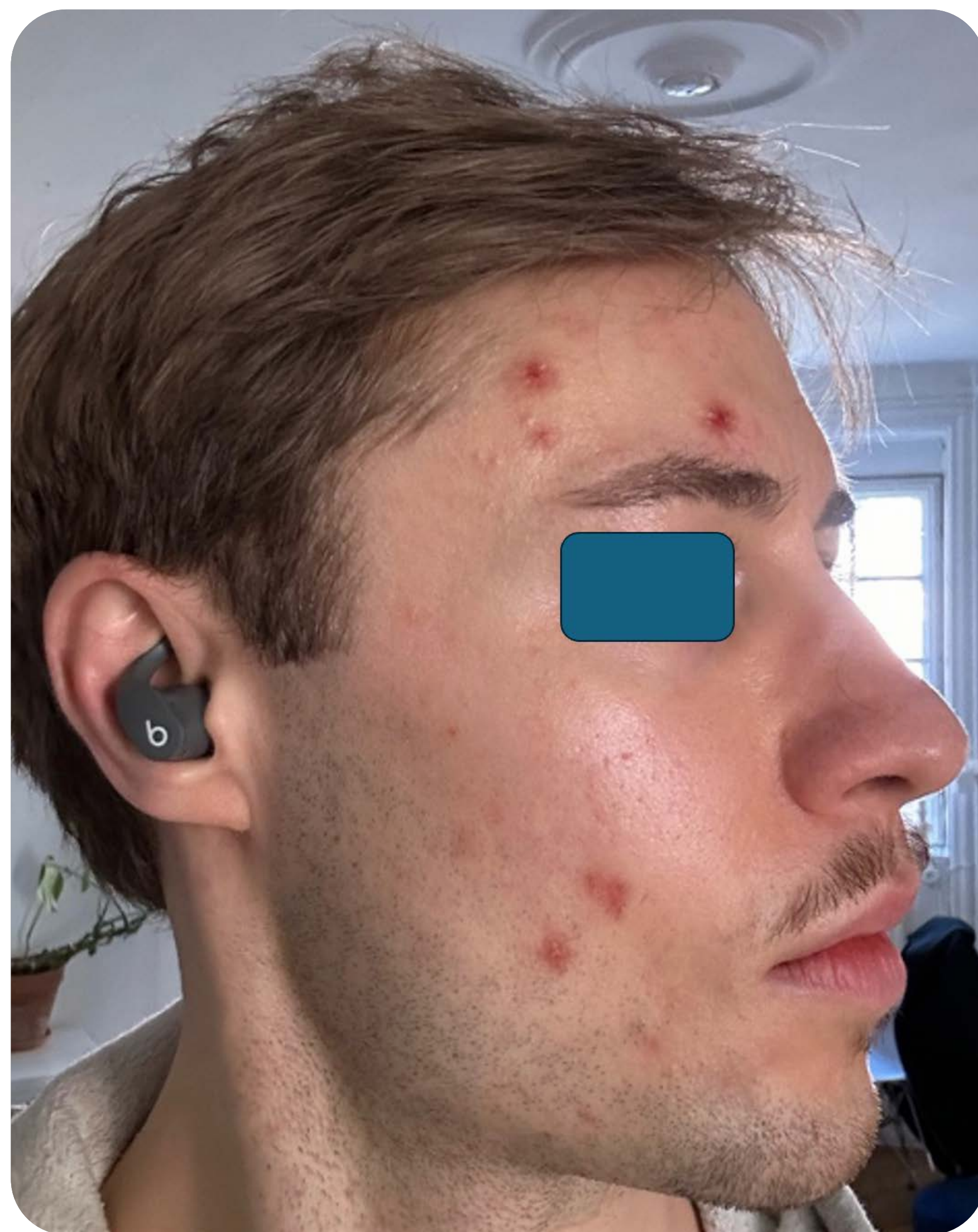* PLASMO®HEAL PRO (Plasmoclean, ApS, Demark)

Use of indirect, 3-dimensional, Cold Atmospheric Plasma-Aerosol (CAP-A) in severe Acne. A Case Report.

Aim:

CAP-A has gained attention as a non-invasive and non-pharmacological therapeutic approach due to its Reactive Oxygen Species (ROS). Therefore, it was used in a patient with acne including facial papules, pustules noduli and cysts associated with pain, and a cosmetic appearance affecting quality of life for years.

The present patient had been treated with topical and systematic modalities including long courses of antibiotics and isotretinoin with limited effect for 10 years (until a year before start with CAP-A).



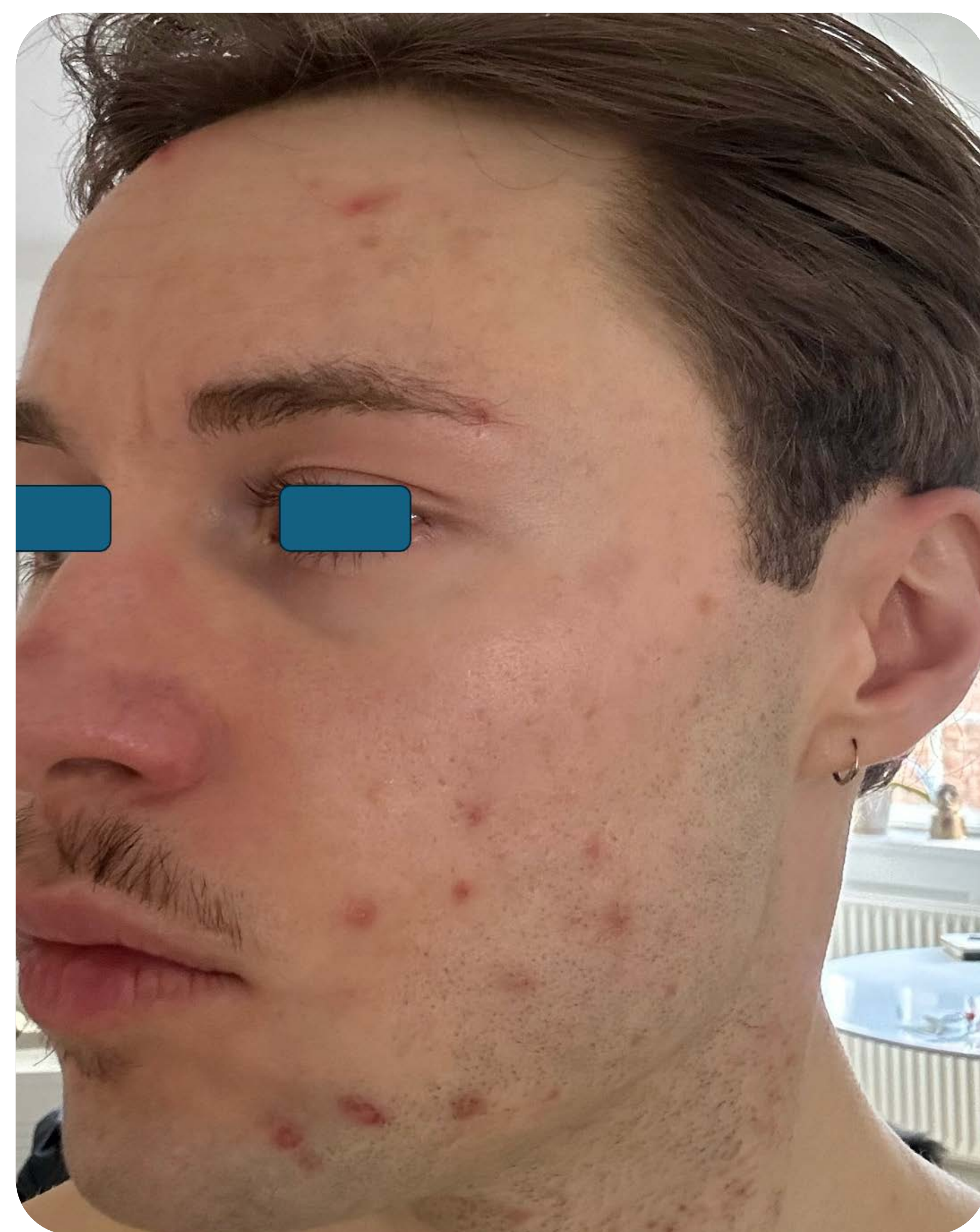
Before Treatment: Acne at the left and right as well as frontal view

Use of indirect, 3-dimensional, Cold Atmospheric Plasma-Aerosol (CAP-A) in severe Acne. A Case Report.

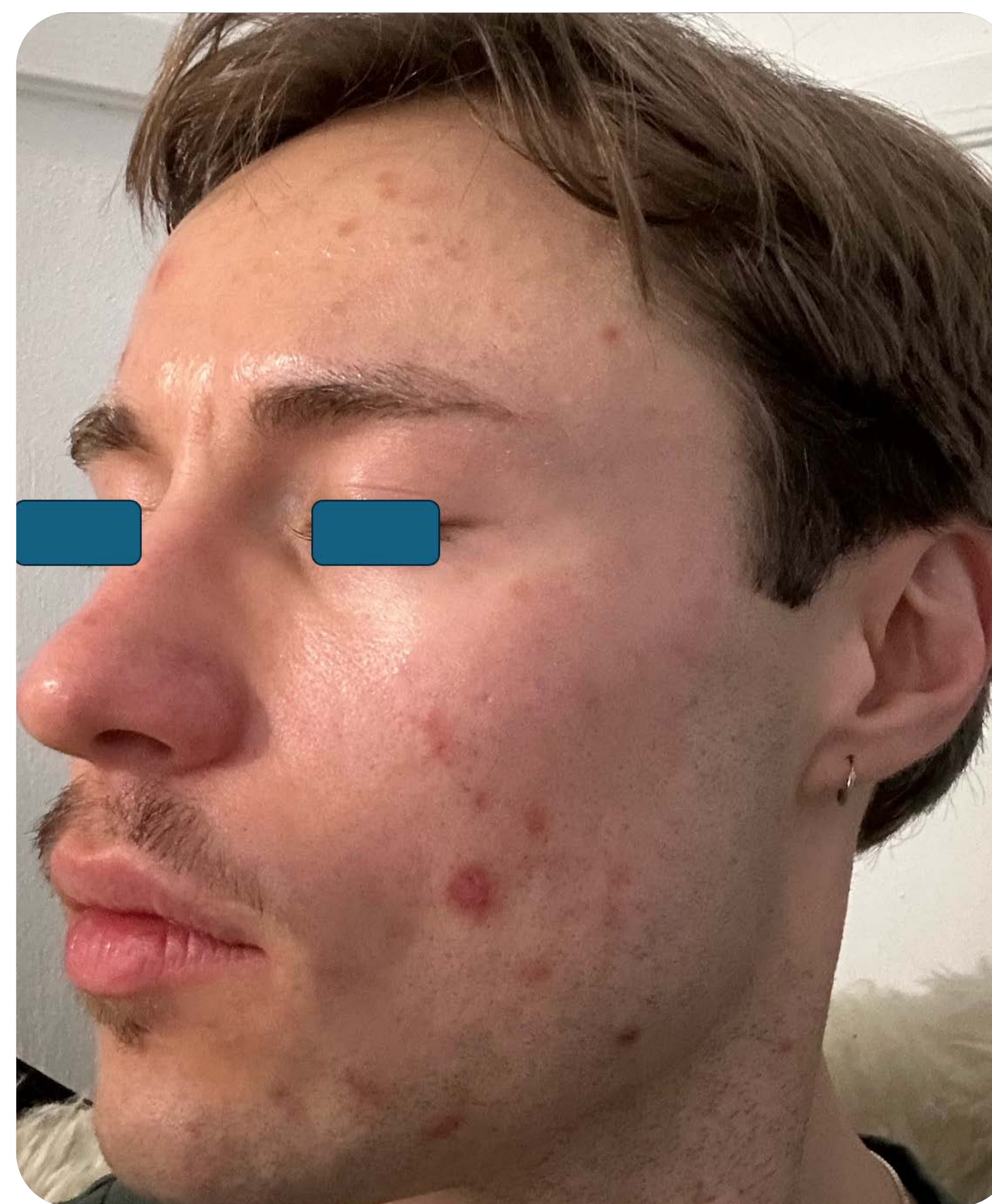Method:

CAP-A was applied at a distance of 3-7 cm from affected skin; initially 3 times weekly for two weeks; each session 3 minutes at cheeks and forehead (3 locations).

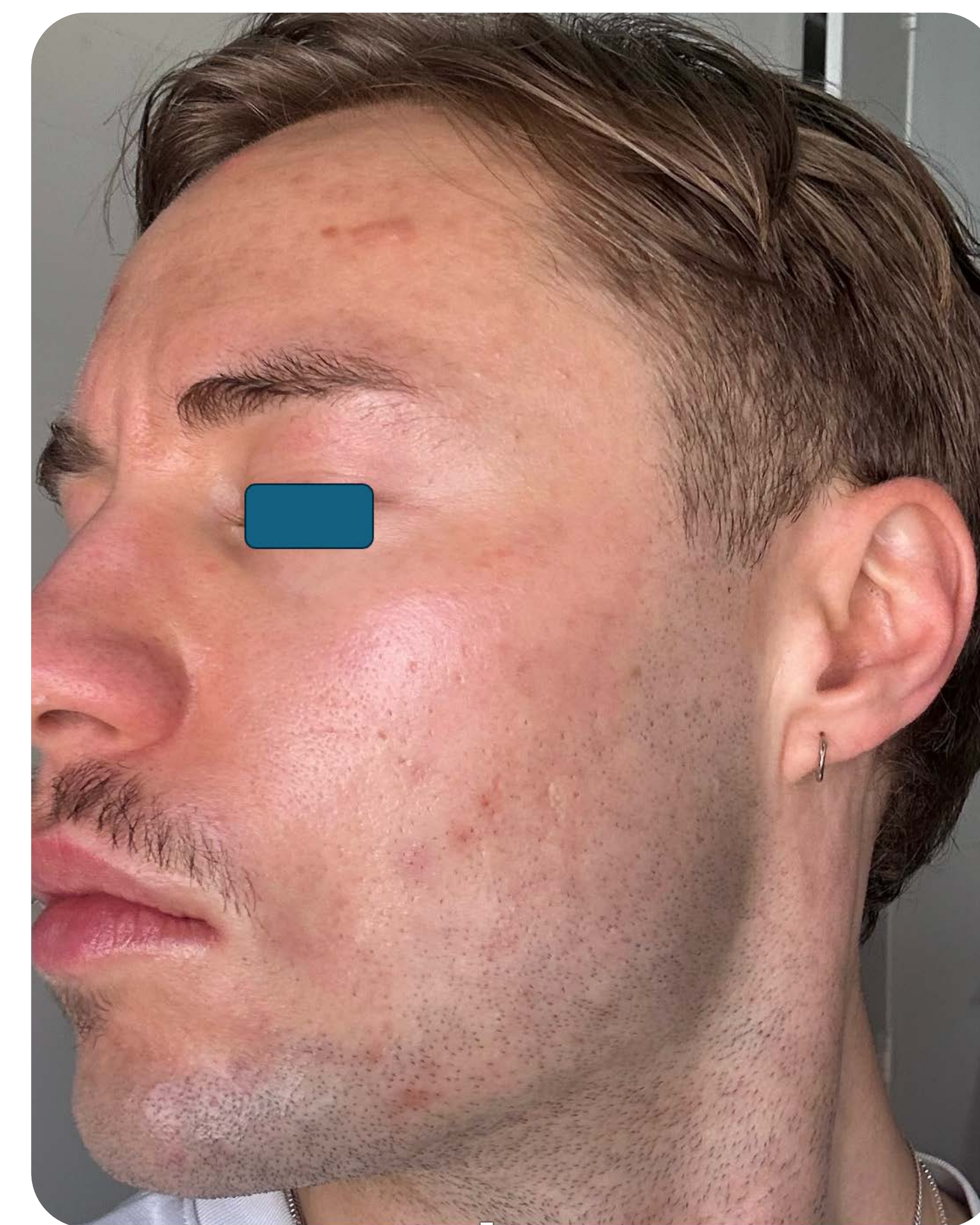As the effect was insufficient the patient was switched to self-treatment with application of CAP-A 3 times daily for 3 minutes for additional 3 consecutive days.



Before Treatment



Day 11 of Treatment

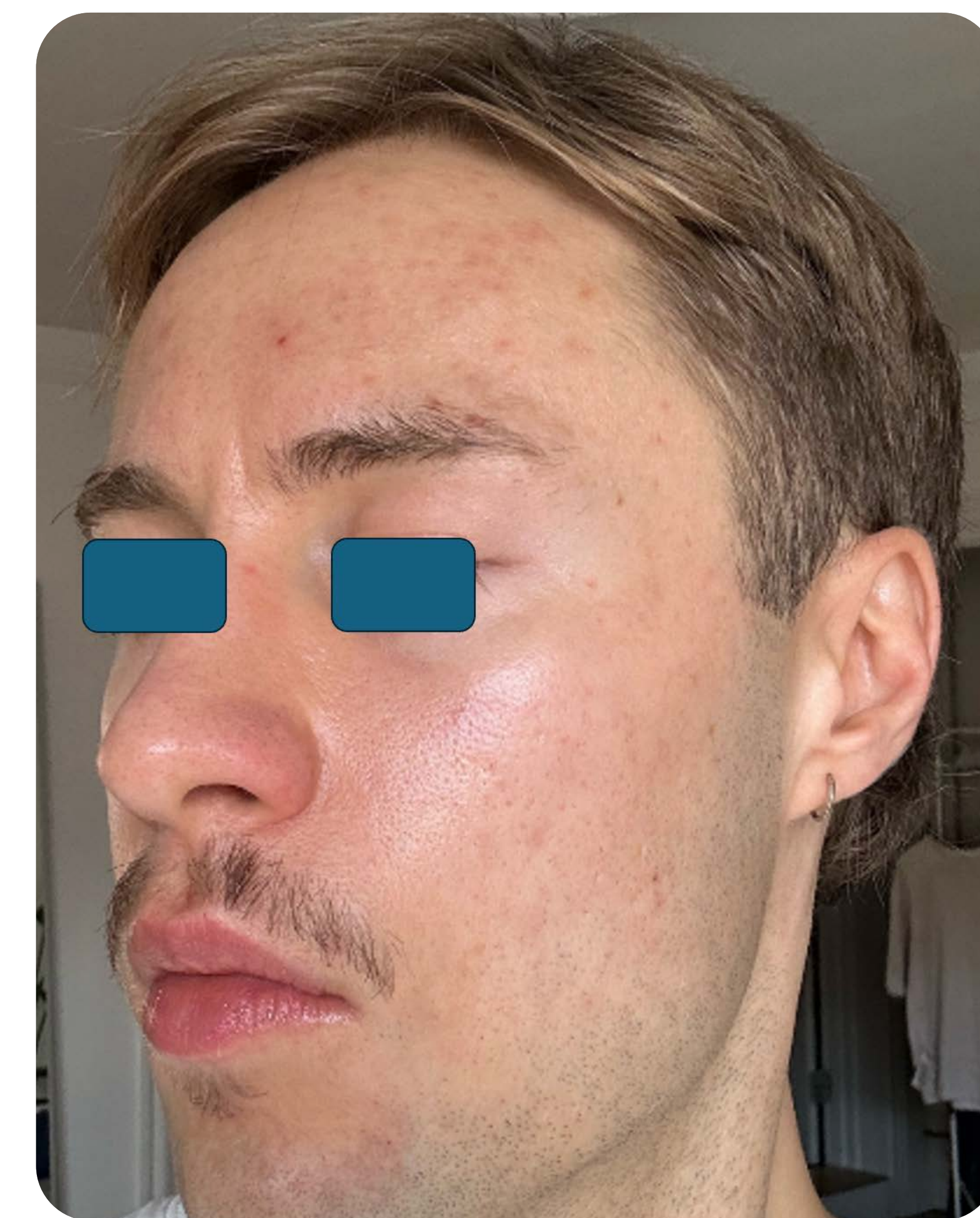
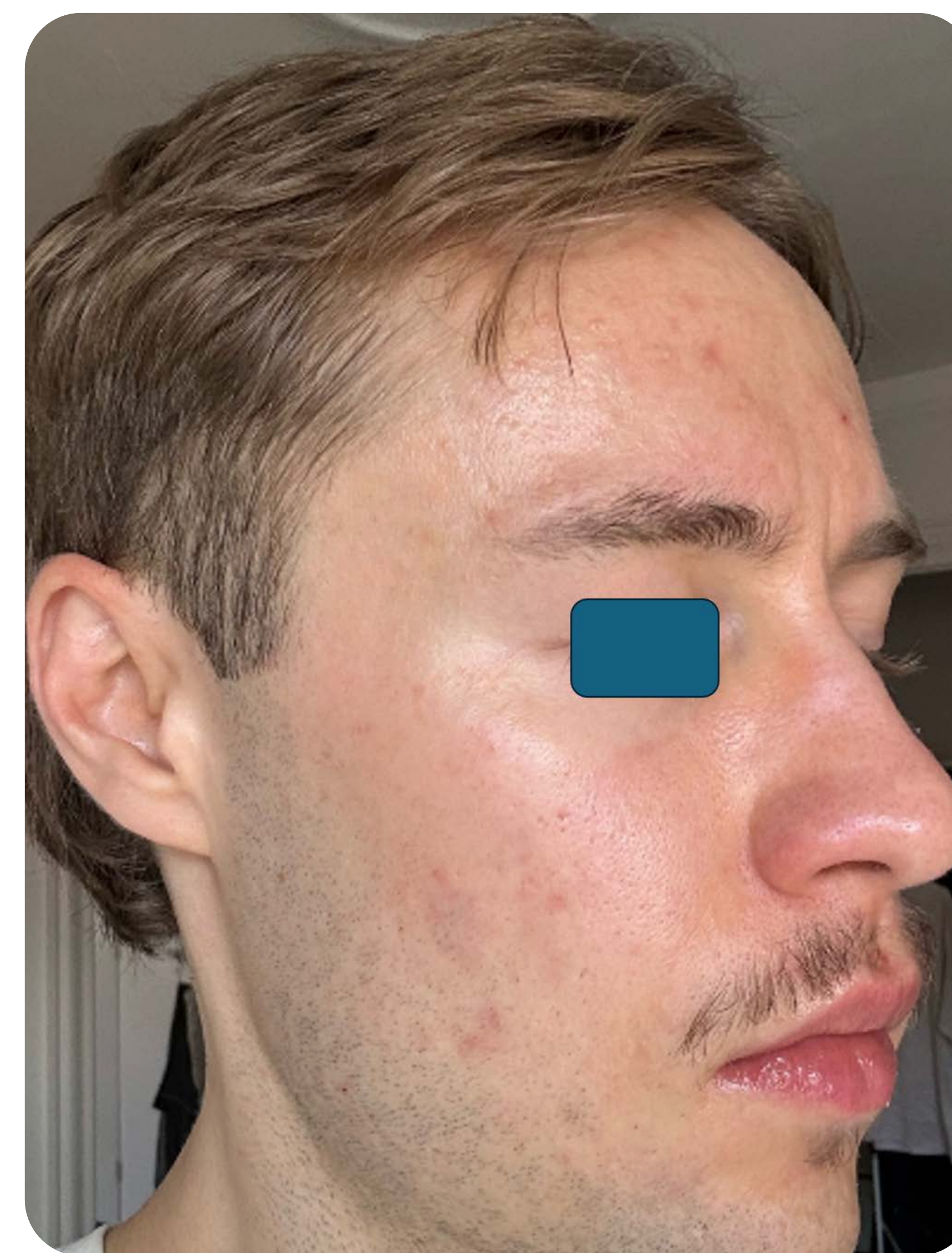
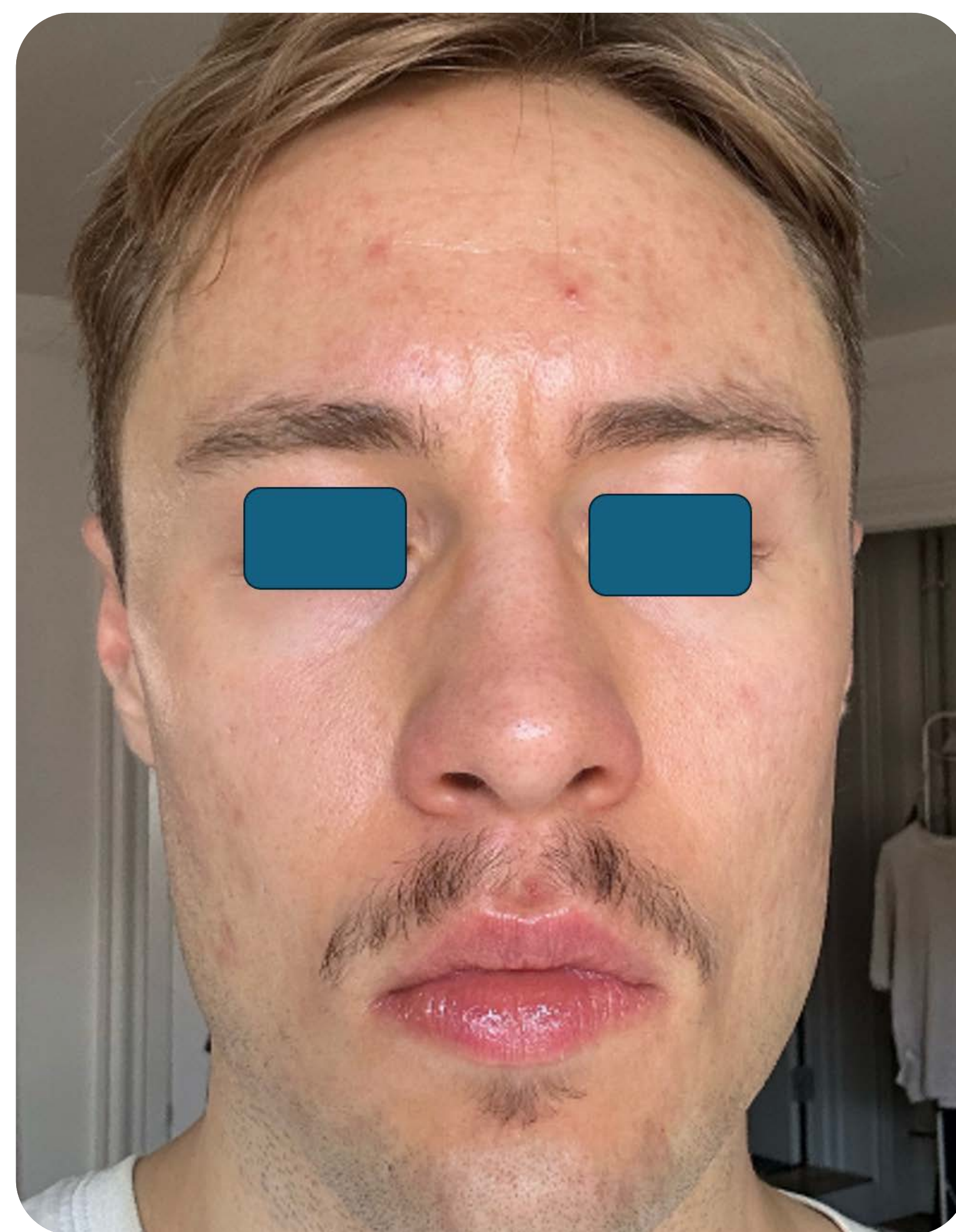10 Days Post-Treatment

Use of indirect, 3-dimensional, Cold Atmospheric Plasma-Aerosol (CAP-A) in severe Acne. A Case Report.

A relapse was seen 4.5 months after therapy and CAP-A self-treatment was restarted: Twice daily for 3 minutes on the 3 anatomic areas for two weeks.

Due to insufficient effect, CAP-A was used for additional two weeks, 3 times daily until all elements of acne vulgaris were erased.



2.5 Months Post-Treatment

Use of indirect, 3-dimensional, Cold Atmospheric Plasma-Aerosol (CAP-A) in severe Acne. A Case Report.

Results:

CAP-A resulted in complete cessation of active acne following 17 days of therapy.
The effect reached its peak 10 days post-treatment lasting for 4.5 months when a new episode of severe acne was seen.

Renewed application of CAP-A for 4 weeks resulted in complete normalisation of the facial skin for the last 1.5 year.

Conclusion:

To our knowledge, this is the first documented case of acne vulgaris successfully treated with CAP-A.

The result indicates that this approach offers a safe, effective, non-pharmacological, and cost-effective therapy as an alternative for conventional treatment.

